

Assess Transcriptionally Active HPV Biomarkers in Head and Neck Cancer Biopsies

Detect HPV E6/E7 mRNA expression with tissue morphological context

- High Sensitivity and Specificity—single molecule detection with single-target specificity by proprietary probe design and detection technology
- Broadest Spectrum—with flexibility of individual genotyping, pooled high-risk and low-risk panels (HPV-HR7, HPV-HR18, HPV-LR6) and custom pooled panels
- Robust and Easy Methodology—scalable with automation for routine analysis

Detection of Gold-standard E6/E7 Oncogene Transcripts Using RNAscope® ISH

Evidence for transcriptional activity of the viral oncogenes *E6/E7* is regarded as the gold standard for presence of clinically relevant high-risk human papillomavirus (HPV), but detection of *E6/E7* mRNA can be challenging using conventional techniques (Bishop *et al.*, 2013). As a causal agent in head and neck squamous cell carcinoma (HNSCC), it is critical that the detection method enable pathologist review of tissue morphology and be of the highest specificity and sensitivity for accurate assessment of within the tissue microenvironment of FFPE specimens (Figure 1, 2). RNAscope® HPV Biomarker Detection Reagents and its proprietary “double Z” oligonucleotide probes specific for each subtype *E6/E7* mRNA enable high specificity detection of viral transcripts in routine FFPE tumor biopsies.

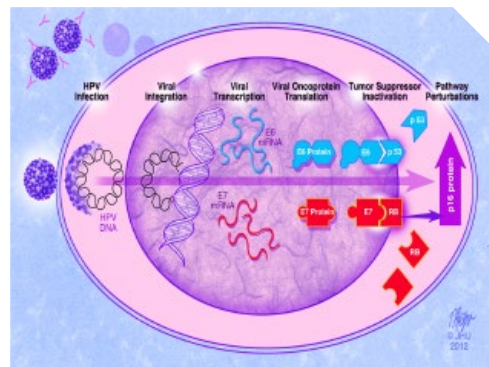


FIGURE 1. Schematic illustration of the Biology of HPV infection provides points of HPV Detection (Bishop *et al.*). Testing *E6/E7* transcripts by RNA ISH is desirable because it indicates the presence of transcriptionally active virus and enables visualization of viral transcripts directly in tumor cells in tissue sections, unlike RT-PCR (Upko *et al.*, 2011).

Highest Sensitivity and Specificity

Current methodologies for HPV testing include PCR-based amplification and DNA *in situ* Hybridization (ISH). PCR amplification of HPV DNA is more sensitive, but it is less specific than DNA ISH. Published studies (Bishop *et al.*, 2013, Upko *et al.*, 2011, and Schache *et al.*, 2013) indicate that RNAscope-based ISH assay is more sensitive than DNA ISH in detecting HPV in Oropharyngeal Squamous Cell Carcinoma (OSCC) and results correlate well with p16 immunohistochemistry (IHC) staining (Table 1).

RNAscope® ISH technology is an ideal platform giving the high sensitivity and specificity needed for detection of HPV biomarkers in Head and Neck Squamous Cell Carcinoma (HNSCC) samples.

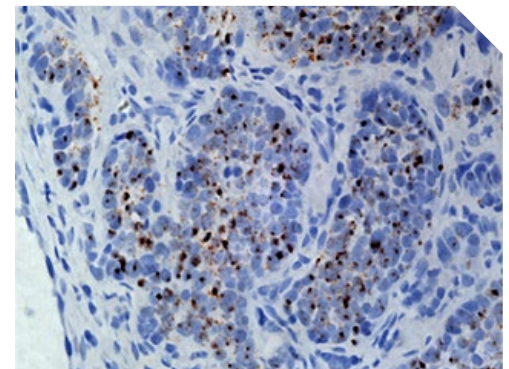


FIGURE 2. High risk HPV *E6/E7* mRNA expression in Head and Neck Squamous Cell Carcinoma (HNSCC). FFPE section of HNSCC hybridized with a pool of HPV 16, 18, 31, 33, 35, 52 and 58 genotype probes, showing cytoplasmic punctate dots only in the tumor cells (40X magnification).



MOLECULAR DETECTION +
MORPHOLOGICAL CONTEXT
IN A SINGLE ASSAY

Assay Methods	Sensitivity	Specificity	PPV	NPV
P16 IHC	97%	82%	80%	97%
HR-HPV DNA ISH	94%	91%	89%	95%
Combined p16/ HR-HPV DNA ISH	94%	91%	89%	95%
DNA qPCR	91%	87%	83%	93%
Combined p16/ DNA qPCR	91%	93%	91%	93%
RNAscope® HR-HPV	97%	93%	91%	98%

TABLE 1. Using the current “gold-standard” qPCR as the reference method, RNAscope® technology demonstrated the best sensitivity and specificity for HPV status determination than existing methods (Schache *et al.*, 2013). Abbreviations: IHC=immunohistochemistry; ISH=*in situ* hybridization; NPV=negative predictive value; PPV=positive predictive value; qPCR=quantitative PCR

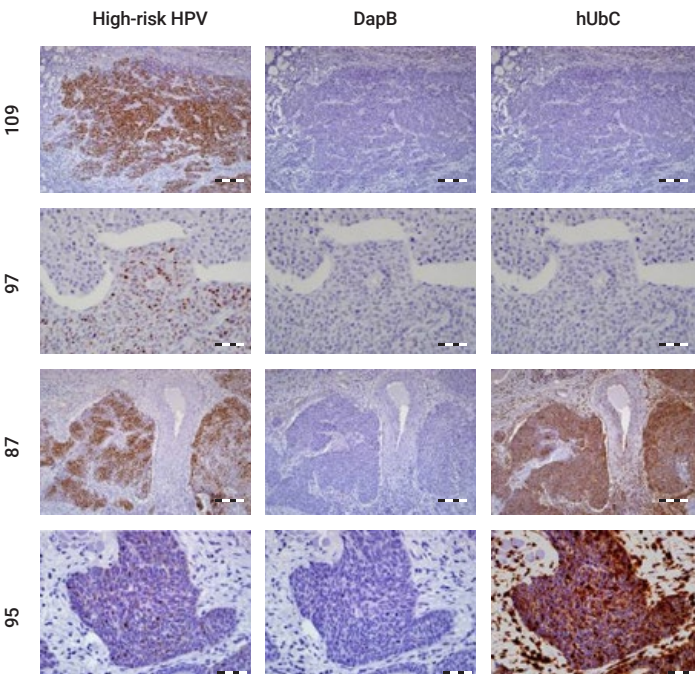


FIGURE 3. Detection of HPV E6/E7 mRNA in oropharyngeal squamous cell carcinoma using RNAscope® VS Reagent Kit-BROWN with probes for high-risk HPV, dapB (negative control) and UBC (positive control) showing a range of positive staining patterns for high-risk HPV: Cases 109 and 97 - strong and moderate staining. Case 87 - strong staining. Case 95 - weak staining. Scale bars: 200 µm for cases 109 and 87 and 50 µm for cases 97 and 95.

High Concordance between p16-IHC and RNAscope® ISH

Case Study: Upko *et al.*, 2011

Here the authors studied 211 oropharyngeal squamous cell carcinoma using tissue microarrays (TMAs) and observed high concordance between RNA ISH and p16 IHC, as well as superior sensitivity of RNA ISH to HPV DNA ISH (Figure 3).

Overall RNA ISH showed a consistently strong, diffuse granular (and or punctate) staining pattern in the tumor cells. The results are more readily visualized than those from DNA ISH

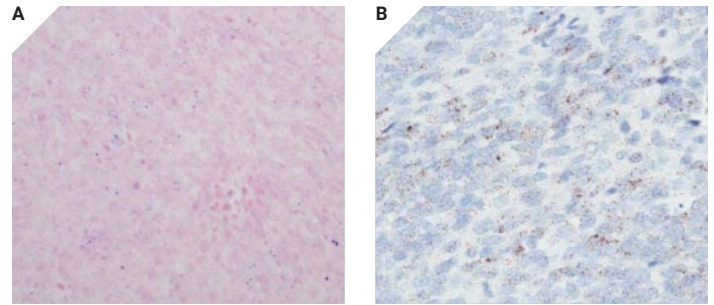


FIGURE 4. High Concordance with DNA and RNA E6/E7 ISH for HR HPV (Upko *et al.*, 2011). A shows positive DNA ISH with the Ventana III assay with punctate, blue, nuclear staining (magnification, 400X). B shows positive RNA ISH with the same with diffuse, finely granular, cytoplasmic staining (magnification, 400X).

High Sensitivity of RNAscope® ISH Independent of Viral Load

Case Study: Bishop *et al.*, 2013

In this study, the authors showed that the RNAscope® ISH Assay was successful in the detection of HPV biomarkers—even in samples with very low viral load.

HPV-related Oropharyngeal squamous cell carcinoma HPV was not detected using Ventana DNA ISH, but low copy numbers were observed by using HPV 16-specific probe with the Dako GenPoint™ assay (Figure 4, Panel B and C).

Using the RNAscope® assay, E6/E7 mRNA transcripts are clearly detected as numerous granular signals (Figure 4, Panel D). Here, the authors confirmed that most oropharyngeal squamous cell carcinomas harbor transcriptionally active HPV.

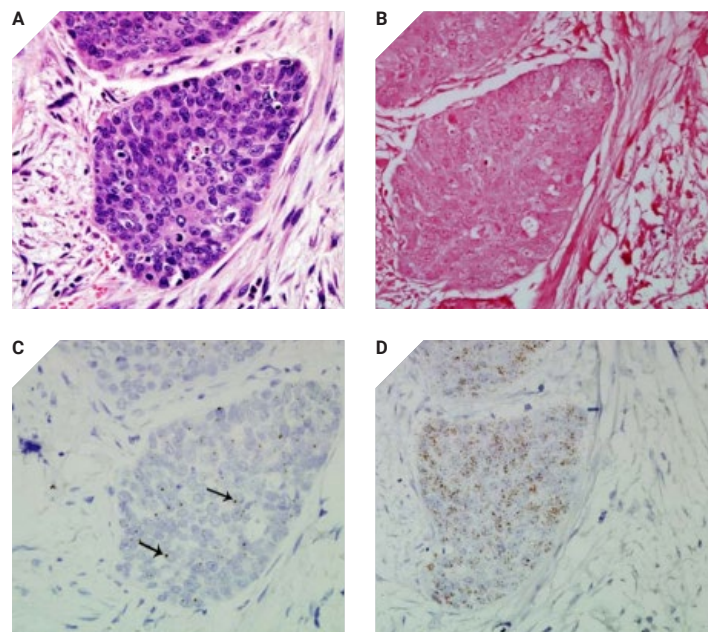


FIGURE 5. HPV-related oropharyngeal squamous cell carcinoma detection (Bishop *et al.*, 2013). A is stained with hematoxylin & eosin stain. B indicates that HPV was not detected using the Ventana Inform HPV III Family 16 probe. C shows the presence of HPV at low viral copy numbers using the type 16-specific probe (arrows point to small hybridization signals within nuclei of tumor cells). D clearly shows mRNA transcripts are seen as numerous granular signals.

HPV Quantitative Molecular Detection Coupled with Morphological Context

Broadest Spectrum HPV Quantitative Molecular Detection

HPV tumor status is the most powerful prognostic indicator for patients with head and neck cancer. Research has indicated that with the same treatment HPV positive cancer cases had a better overall survival: 80 to 85% versus approximately 35 to 38% for HPV negative cancer cases (CAP Today article, 2014). Clinical assessment of HNSCC disease basis requires accurate and comprehensive detection of active HPV subtypes. While > 90% of HPV cases are type 16, an assay assessing all high risk (HR) subtypes is recommended for labs assessing HPV status in HNSCC.

RNAscope® technology offers a broad spectrum of probes targeting 18 High Risk subtypes as well as 6 Low Risk subtypes. The HR 18 HPV types were selected based on thought leader interviews and are in accordance with published literature and the International Agency for Research on Cancer (IARC). Users are able to easily customize probe pools to evaluate specific HPV genotypes.

Routinely used with FFPE and Fresh Frozen Tissues

Extensive assay development was done to ensure that the RNAscope® assay will work with a wide range of tissue types—both FFPE and fresh frozen are routinely used.

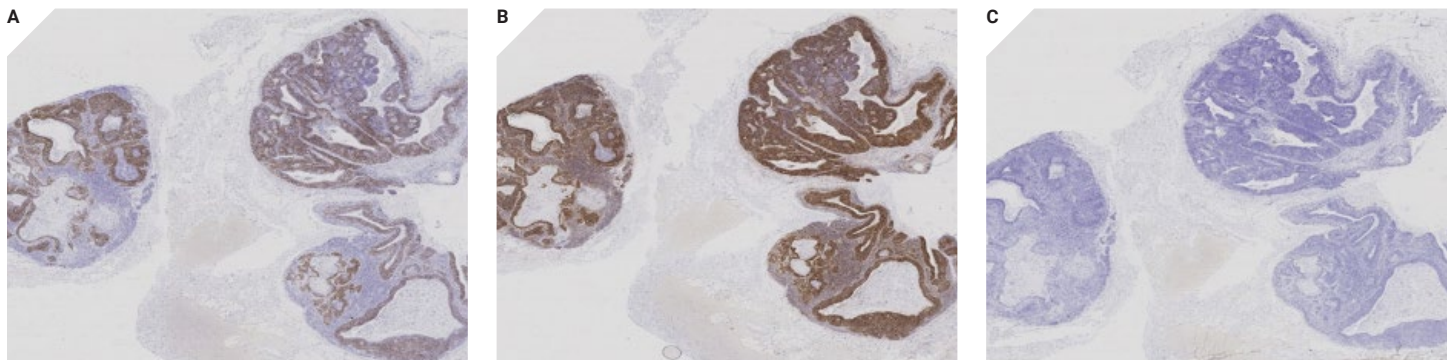


FIGURE 6. High expressing HR-HPV case study using RNAscope® 2.0 HD Assay – BROWN with a positive and a negative control slide. A. HPV-HR18 B. UBC Poitive Control C. DAP B Negative Control

References

1. Bishop JA, Ma XJ, Wang H, Luo Y, Illei PB, Begum S, Taube JM, Koch WM, Westra WH (2012). Detection of Transcriptionally Active High-risk HPV in Patients With Head and Neck Squamous Cell Carcinoma as Visualized by a Novel E6/E7 mRNA *In Situ* Hybridization Method. *American Journal of Surgical Pathology*, 36 (12):1874–1882. doi: 10.1097/PAS.0b013e318265fb2b.
2. Schache AG, Liloglou T, Risk JM, Jones TM, Ma XJ, Wang H, Bui S, Luo Y, Sloan P, Shaw RJ, Robinson M (2013). Validation of a novel diagnostic standard in HPV-positive oropharyngeal squamous cell carcinoma. *British Journal of Cancer*, 108(6):1332–1339. doi: 10.1038/bjc.2013.63.
3. Ukpo OC, Flanagan JJ, Ma XJ, Luo Y, Thorstad WL, Lewis JS Jr (2011). High-Risk Human Papillomavirus E6/E7 mRNA Detection by a Novel *In Situ* Hybridization Assay Strongly Correlates With p16 Expression and Patient Outcomes in Oropharyngeal Squamous Cell Carcinoma. *American J of Surgical Pathology*, 35(9):1343–1350. doi: 10.1097/PAS.0b013e318220e59d.
4. CAP TODAY, Dec 2013 Newsletter.


Tissue Morphological Context

In many labs today, oropharyngeal cancer cases are routinely tested using a surrogate marker, p16-IHC, which may be followed by an extraction assay using RT-PCR to determine HPV involvement. A major concern with an extract assay of HPV is the loss of morphological context, which is essential to establish that active HPV is present in tumor cells. An advantage of RNAscope® ISH is the specific assessment of HPV is in the context of intact tissue morphology. The RNAscope® ISH signal is identified as strong, clear punctate chromogenic dots present in the nucleus and/or cytoplasm. The recommended assay format includes the use of assay control probes, bacterial gene *Dap B* (negative control) and housekeeping gene *UBC* (positive control to verify sample RNA integrity) run on serial sections alongside HPV probe. For positive identification of HPV, the staining should have granular cytoplasmic and/or nuclear brown staining that is measurably higher than the negative *Dap B* control slide (Figure 5).

Robust and Easy Methodology

The RNAscope® ISH workflow is similar to IHC and can be automated. Thousands of off-the-shelf catalog probes and several probe pools are already available. RNAscope® Custom Probes and probe pools are available in less than 3 weeks.

Experience unprecedented molecular specificity and morphological data
in one sensitive assay at www.acdbio.com/hpv-related-cancer



For Research Use Only. Not for diagnostic use. RNAscope is a registered trademark of
Advanced Cell Diagnostics, Inc. in the United States or other countries. All rights reserved.
©2015 Advanced Cell Diagnostics, Inc. Doc #: MK 51-019/Rev A/Effective date 05012016

California, USA